UNIVERSITÉ DE MONTPELLIER

CHRU MONTPELLIER
CENTRE HOSPITALIER REGIONAL UNIVERSITAIRE

Institut de Recherche en Cancérologie
IRC Montpellier

Genomics and imaging data

S Nougaret, MD, PhD, Montpellier, France

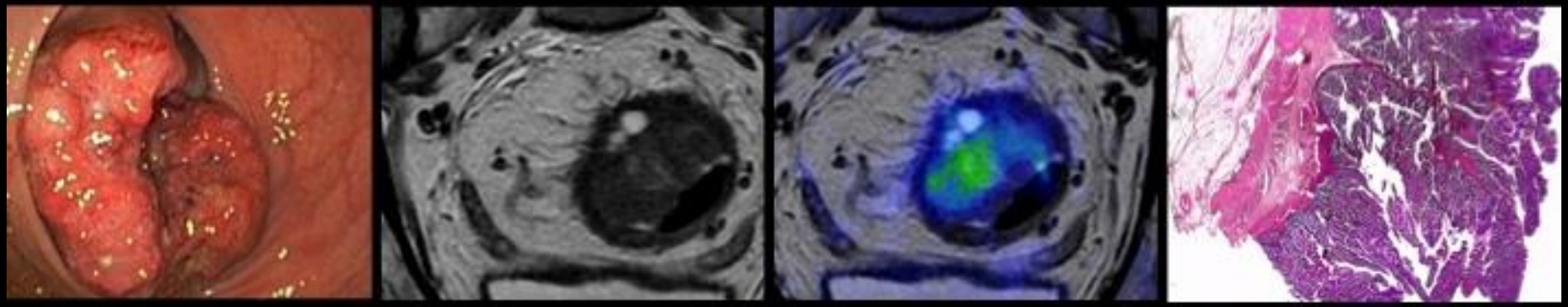

Oncologic Imaging in the Era of Precision Medicine

- Precision medicine: treating the right patient, with the right drug, at the right time, has become the paradigm of modern medicine

- Genomic is essential to this new paradigm



Oncologic Imaging in the Era of Precision Medicine

- Cancer is a genetically heterogeneous disease undergoing continuous evolution - spatially and temporally

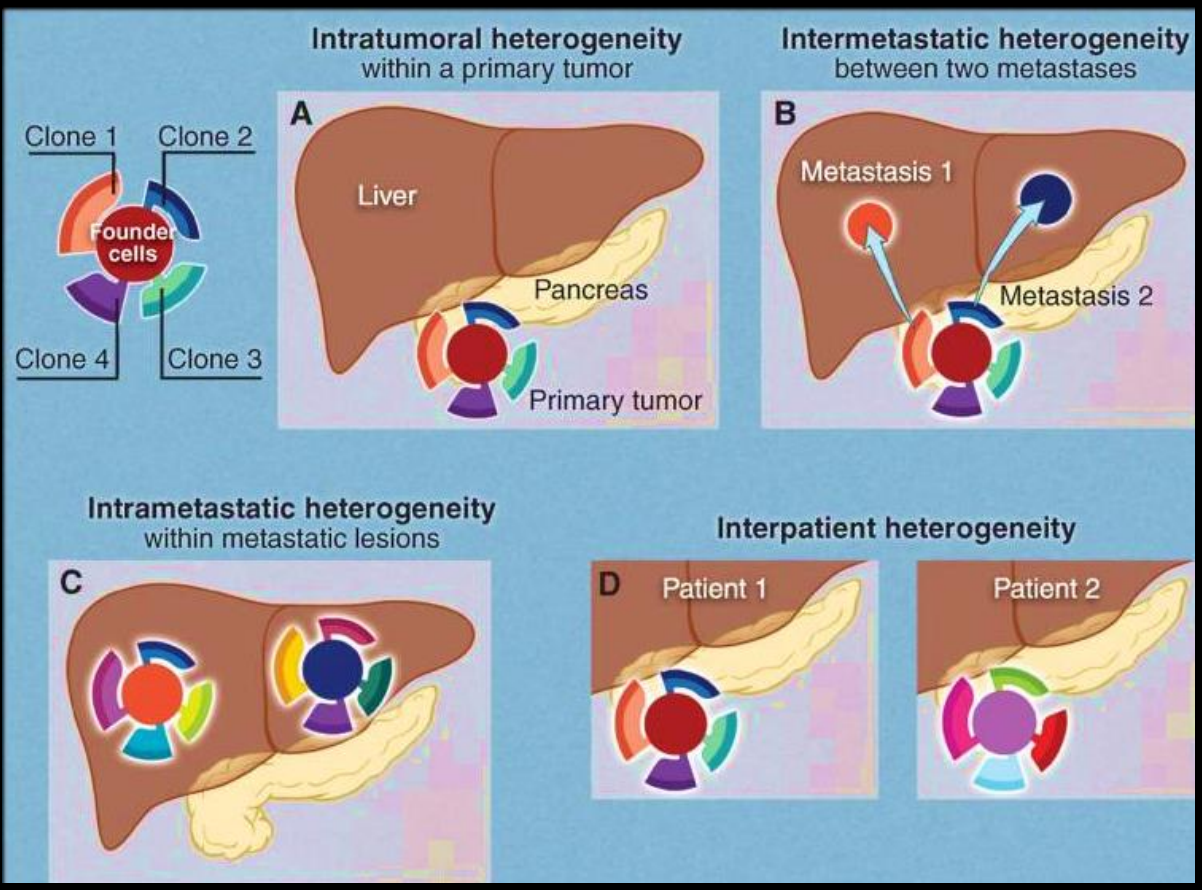

- Primary tumors are spatially and temporally heterogeneous
- Metastasis de-differentiate in 50% of cancers & have different biologic features

Vogelstein et al. Cancer Genomic Landscapes. Science 2013 March 29; 339(6127): 1546-1558

Radiogenomics: Next Generation Sequencing Imaging

Links specific imaging traits (radiophenotypes) with gene-expression profiles

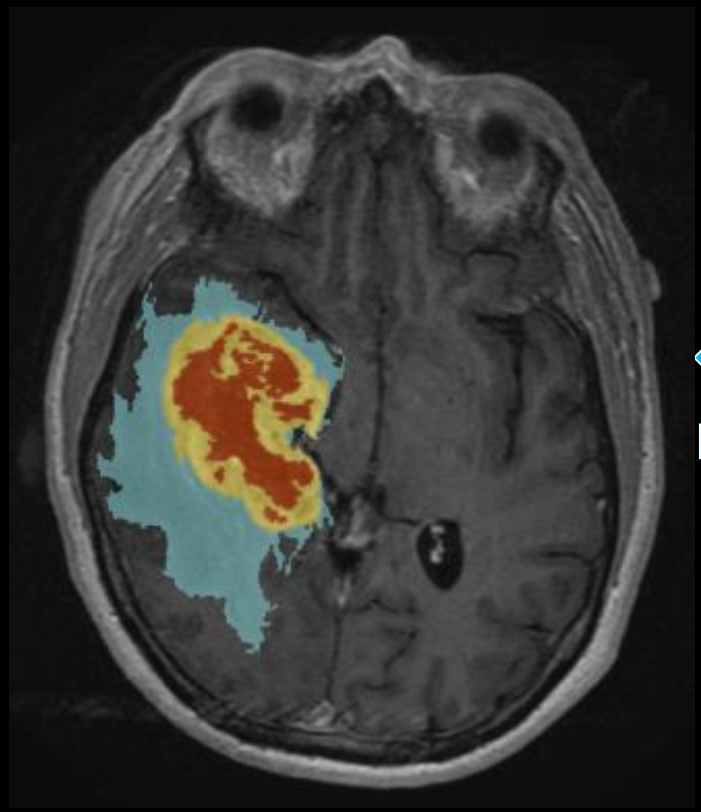

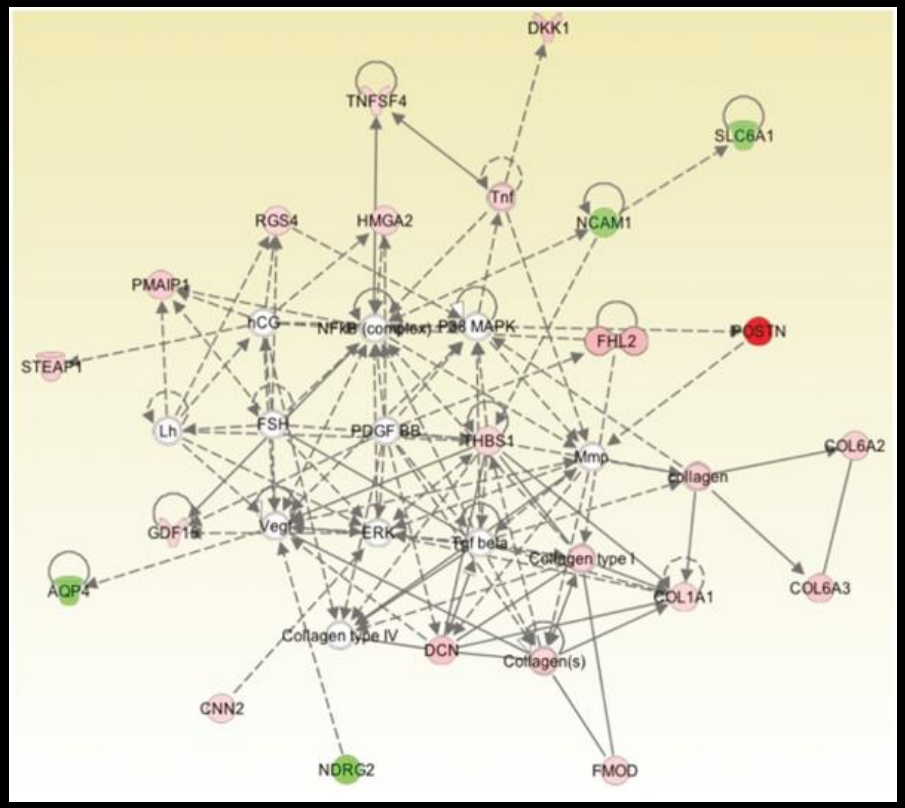

Rivka R. Colen

Kidney Cancer

Advantages of imaging over (multiple) biopsy

- Repeated evaluations of all lesions at different time points
- Assessment of heterogeneity
- Capture of dynamic genomic evolution

Preliminary Data

- 233 clear-cell RCC (TCGA and MSKCC cohorts)
- Mutations: VHL, BAP1, PBRM1, SETD2, KDM5C
- Selected CT Imaging Features
- Retrospective, exploratory design

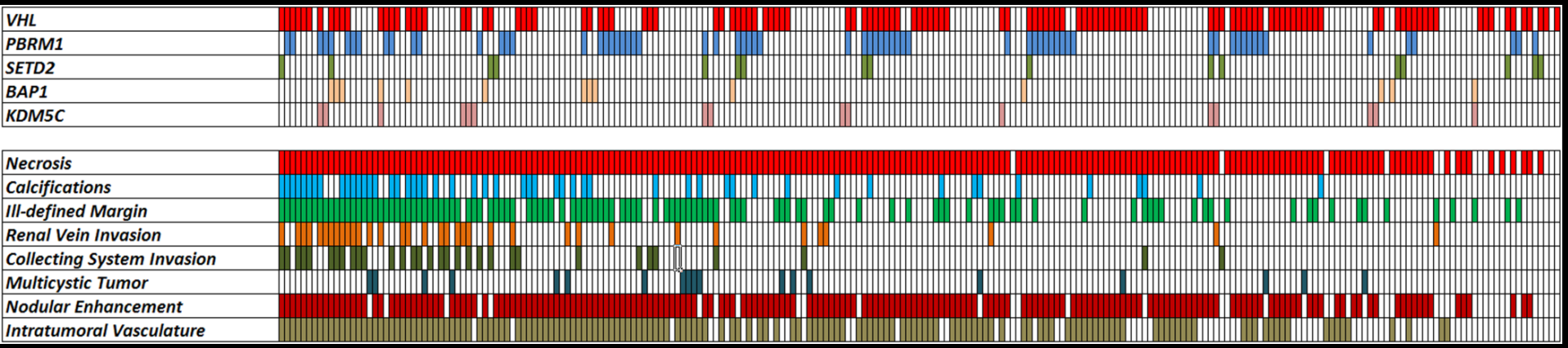

Karlo Radiology. 2013

TCGA NCI Imaging program: Kidney Cancer

Associations:

- Increased vascularity (incl. nodular tumor enhancement) and well-defined margins suggest VHL mutation
- Evidence of renal vein invasion suggests BAP1 & KDM5C
- Multicystic clear cell RCC associated with less mutations (absent BAP1, KDM5C & BAP1) compared to solid clear cell RCC (PBRM1 & VHL more common)
- Potential implications for assessment of tumor aggressiveness and active surveillance

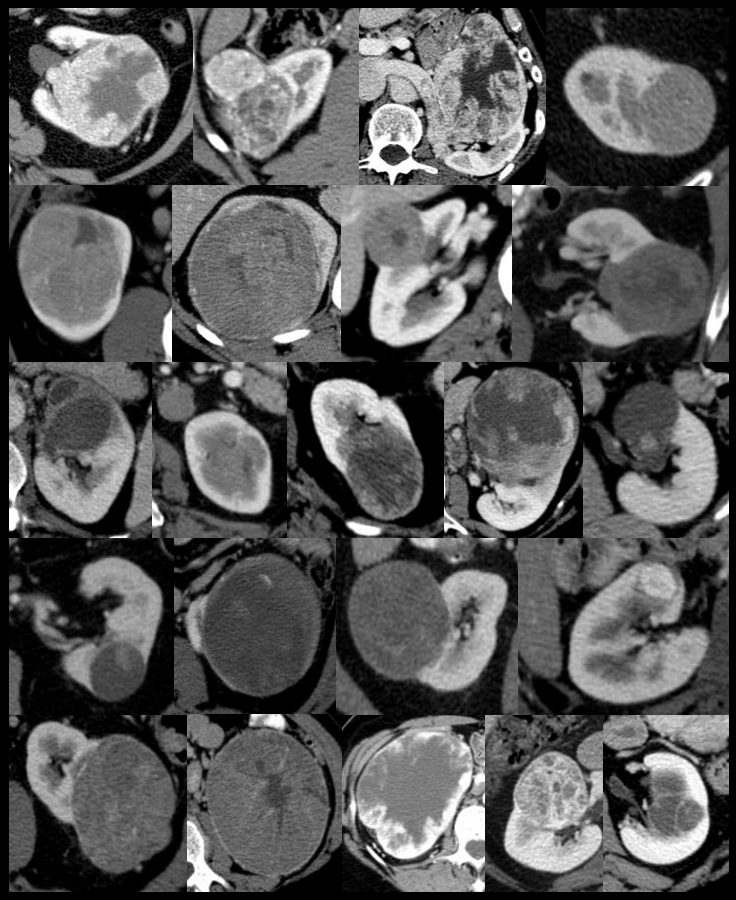

Karlo Radiology. 2013

TCGA NCI Imaging Program: Ovarian Cancer

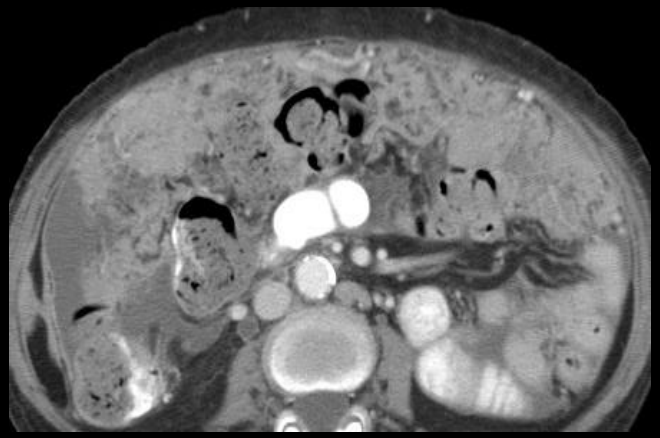

- CLOVAR Mesenchymal subtype associated with diffuse peritoneal disease shape and mesenteric tethering
- Platinum resistant in ~70%
- Lower optimal surgical debulking

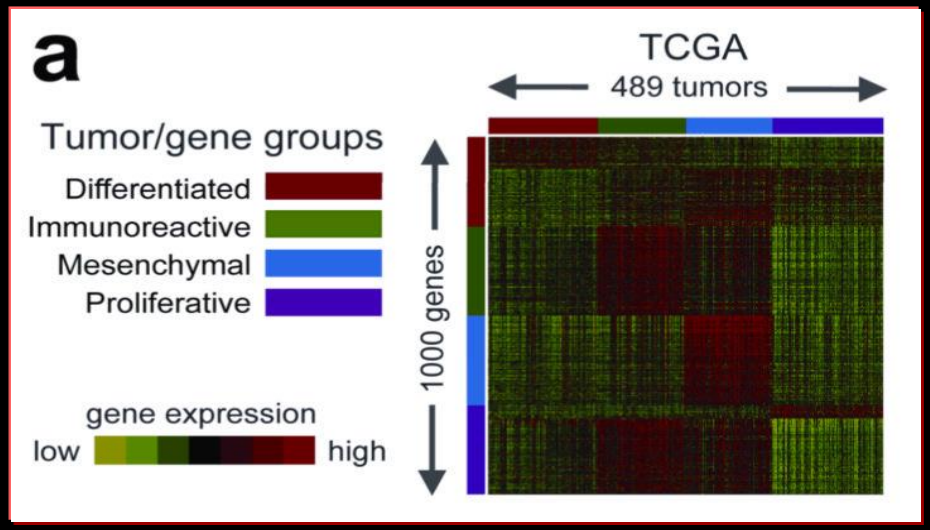

Vargas Radiology. 2015

Memorial Sloan-Kettering Cancer Center

The Best Cancer Care. Anywhere.

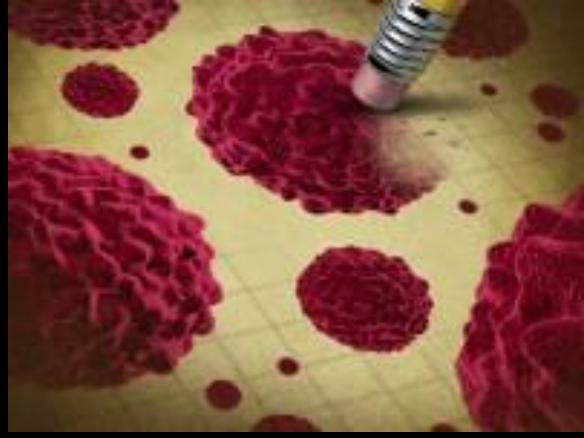

High Grade Serous Ovarian Cancer: BRCA Mutation Status and CT Imaging Phenotypes

Acknowledgments

Sala E- Lakhman Y- Moskowitz C- Goldman D

Rationale

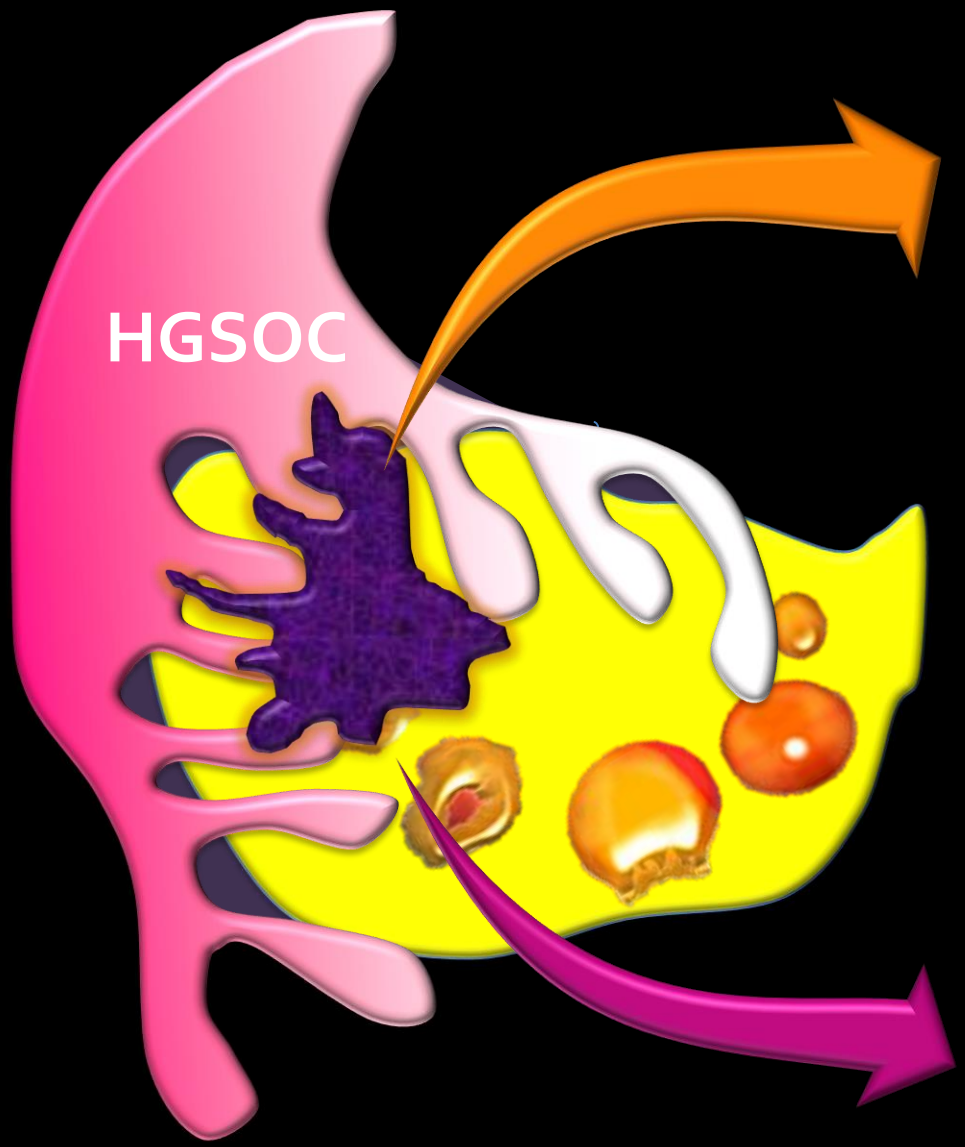

BRCA + (15-17%)

- ✓ Higher response rates to first and subsequent lines of platinum-based Cx
- ✓ Specific chemosensitivity to inhibitors of poly-ADP ribose polymerase
- ✓ Longer relapse free period
- ✓ ? Higher rate of optimal cytoreduction

BRCA – (80%)

- ✓ Lower response rates to first and subsequent lines of platinum-based Cx
- ✓ Shorter relapse free interval

Rationale/Objective

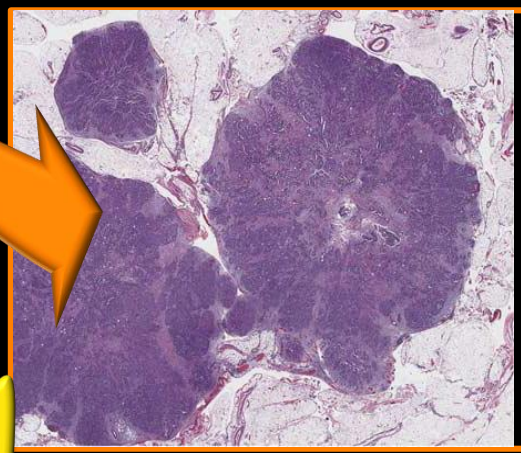

BRCA +

- ✓ "Pushing" and round metastases
- ✓ May be associated with the rate of optimal cytoreduction

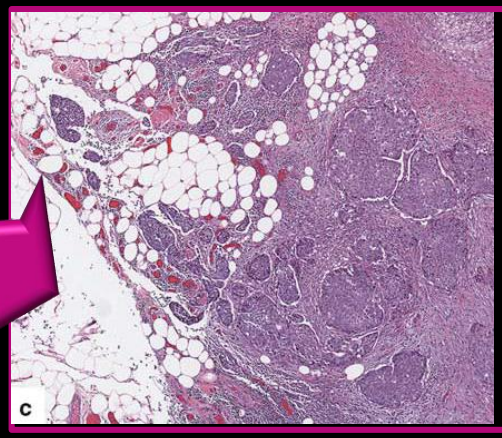

BRCA –

- ✓ Infiltrative pattern

Soslow, Modern Pathology, 2014
Reyes, Modern Pathology, 2014

To evaluate **CT imaging features** that may be associated with presence of **BRCA mutations.**

Materials and Methods

108 Patients with HGSOC
- ✓ Tested for BRCA mutations
- ✓ Primary surgical cytoreduction
- ✓ Pre-operative contrast-enhanced CT

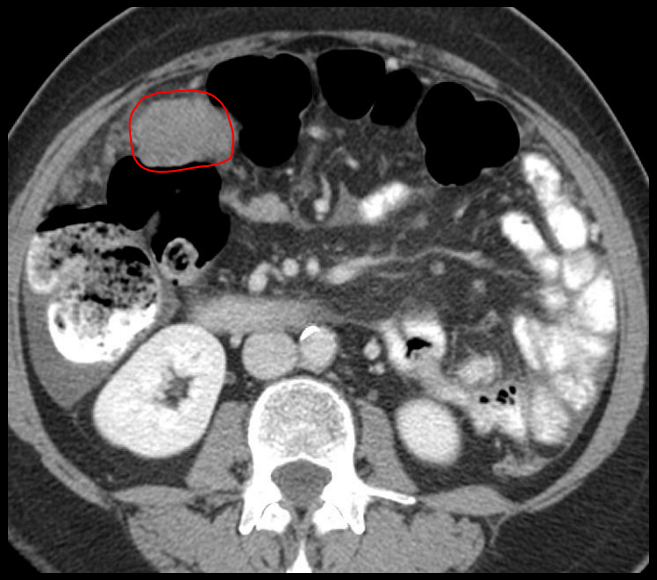

Primary ovarian mass:
- ✓ Margin (smooth or irregular)
- ✓ Mass architecture (cystic, solid)
- ✓ Papillary projections
- ✓ Calcifications

Extent of disease:
- ✓ Peritoneal implant presence and their locations
- ✓ Pattern of peritoneal disease (nodular or infiltrative)
- ✓ Mesenteric involvement
- ✓ Lymphadenopathy

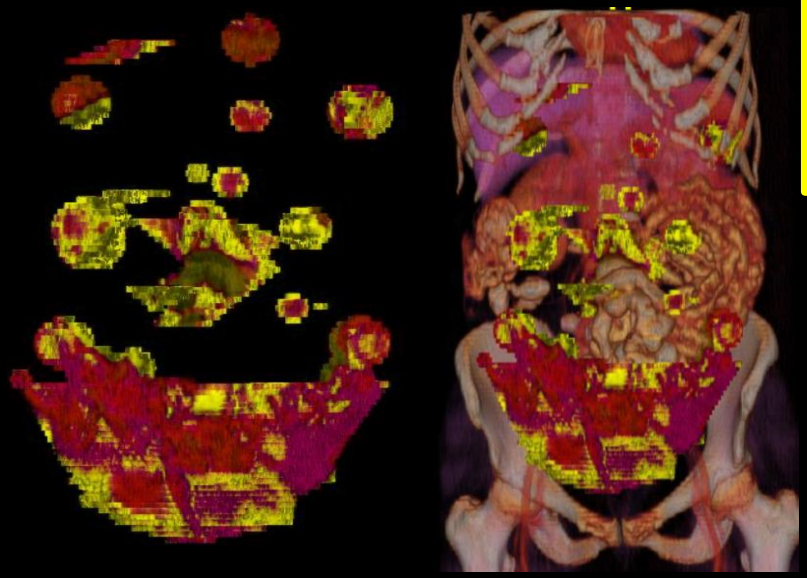

Volume of nodular disease

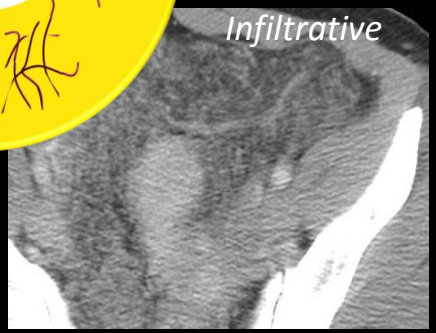

Results

- ✓ Pattern of peritoneal disease varied according to the BRCA mutation status ($p < 0.02$ for both readers).

- ✓ Mesenteric involvement by tumor was more frequent in BRCA - ($p<0.01$ for both readers)

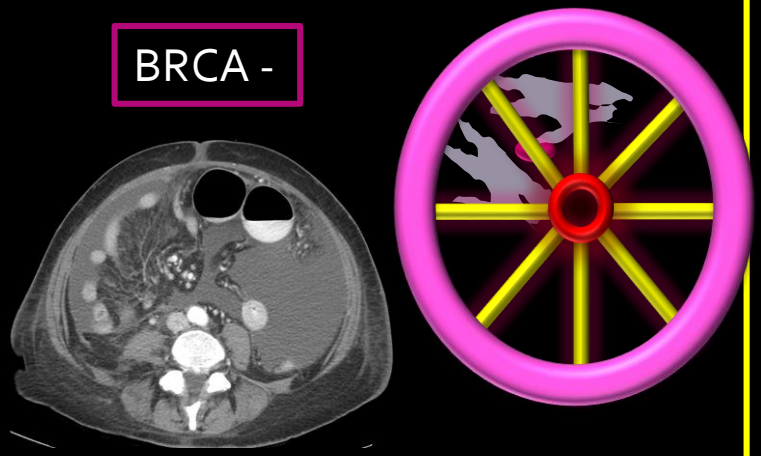

Theradiag
INNOVATION FOR BIOTHERAPIES

Institut de Recherche en Cancérologie
I R C Montpellier

ICM
Institut régional du Cancer
Montpellier | Val d'Aurelle

Rectal Cancer MRI and Transcriptome Sequencing

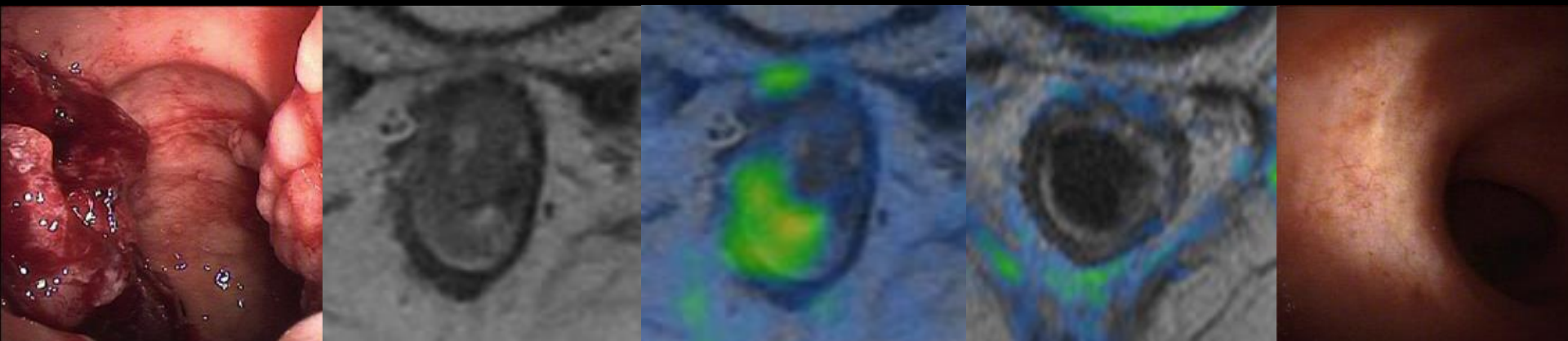

RECTAL CANCER MRI RESPONSE

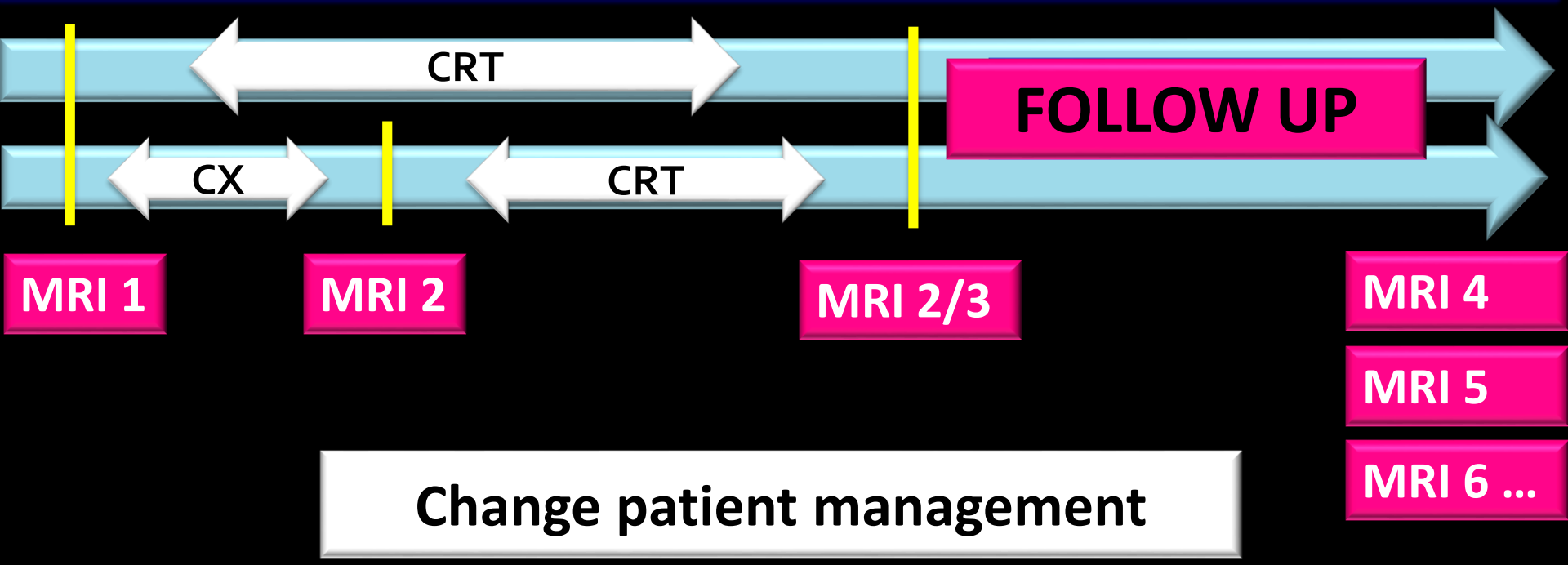

- ✓ ESMO guidelines. Annals Oncology 2012
- ✓ EURECCA-CRC consensus guidelines EJC 2014.
- ✓ ESGAR consensus guidelines Eur Radiol 2013

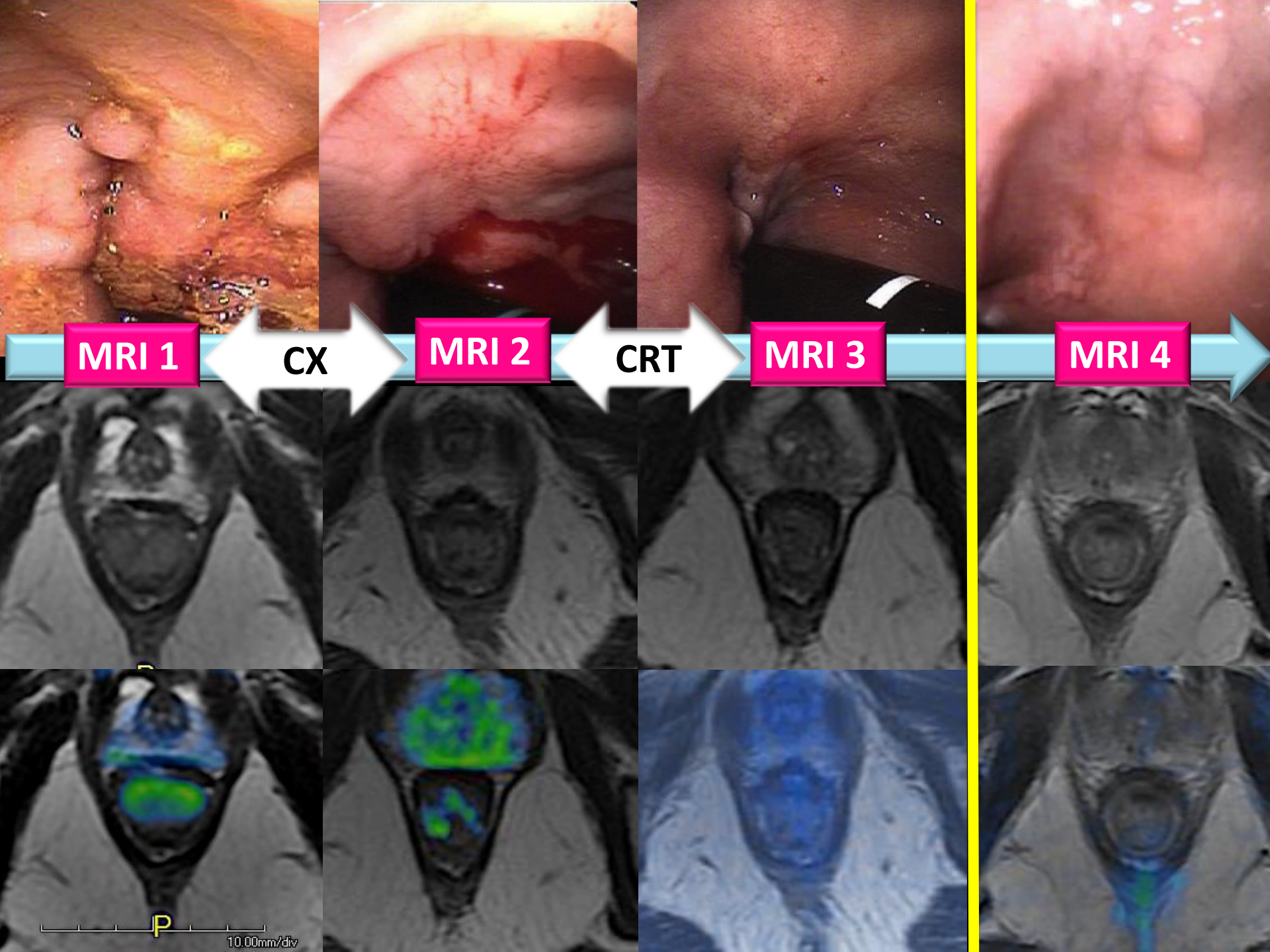
MRI 1
CX
MRI 2
CRT
MRI 3
MRI 4
P
10.00mm/div

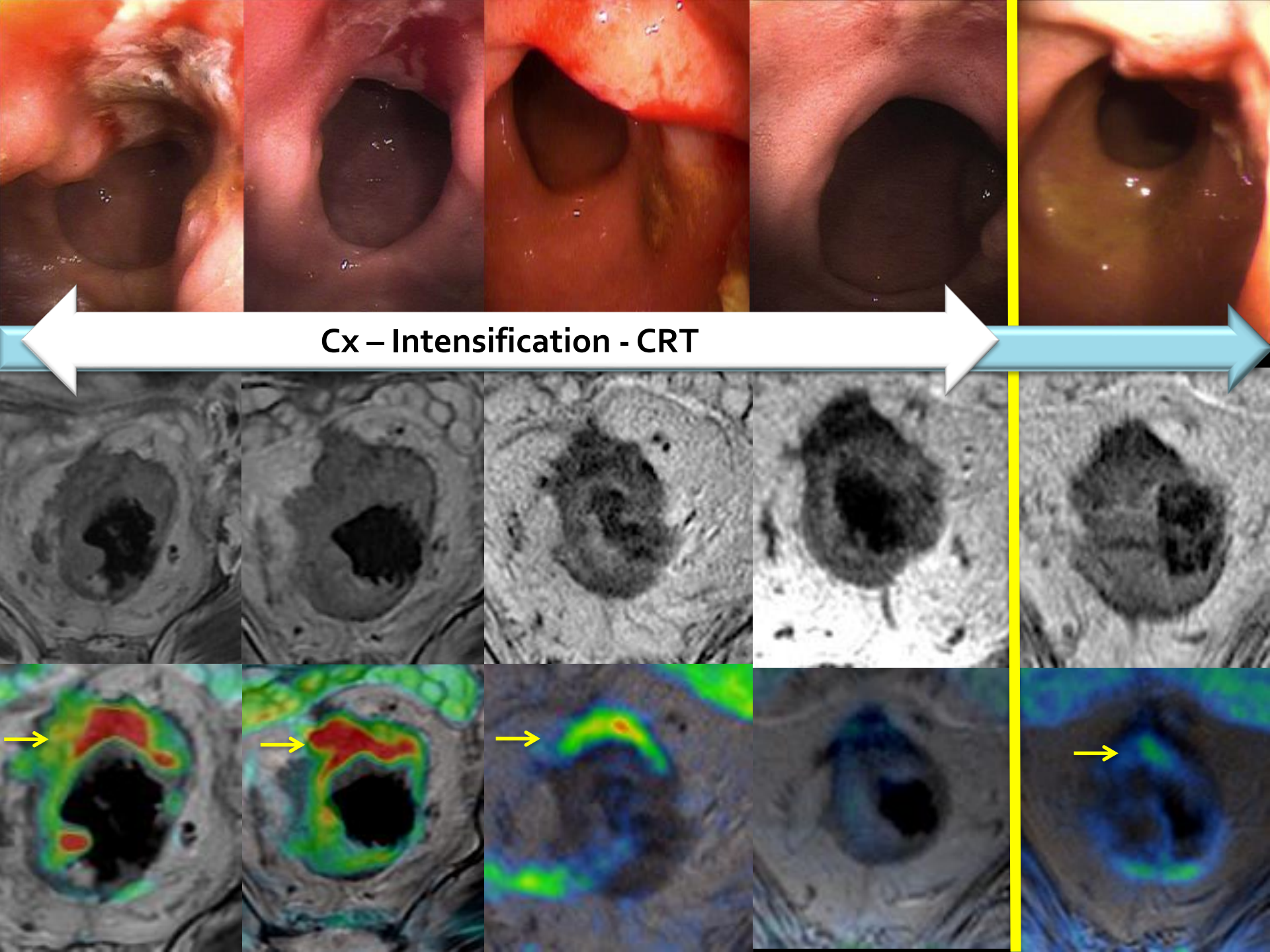
Cx – Intensification - CRT

MRI BIOMARKERS:

DWI

Before CRT

After CRT

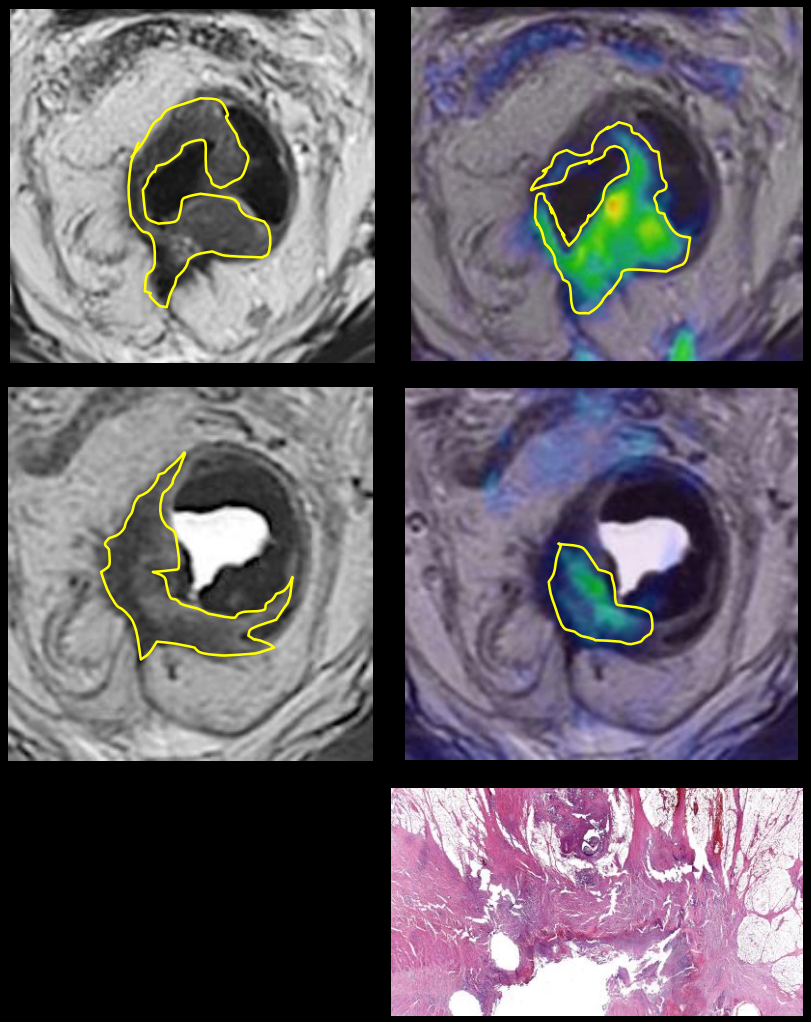

MRI TRG

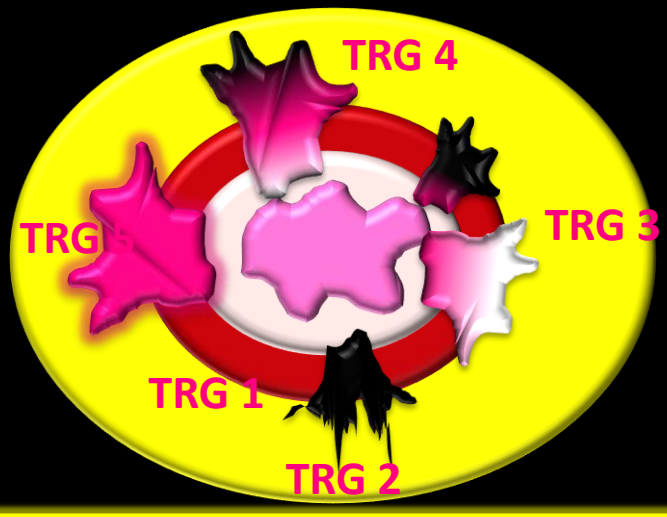

TRG 5: No response, same appearance as original tumor
TRG 4: Slight response: small areas of fibrosis or mucin, but mostly tumor
TRG 3: Moderate response: > 50% fibrosis or mucin, and visible tumor (2 drawings: fibrosis: dark, mucin: grey panel)
TRG 2: Good response: dense fibrosis (>75%) ; no obvious residual tumor or minimal residual tumor
TRG 1: Complete radiologic response: no evidence of any abnormality

VOLUMETRY

Patel, JCO, 2011
Nougaret, Radiology 2012
Nougaret, Radiology 2015

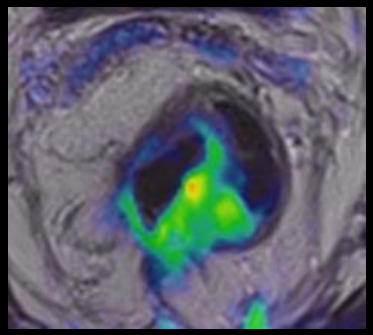

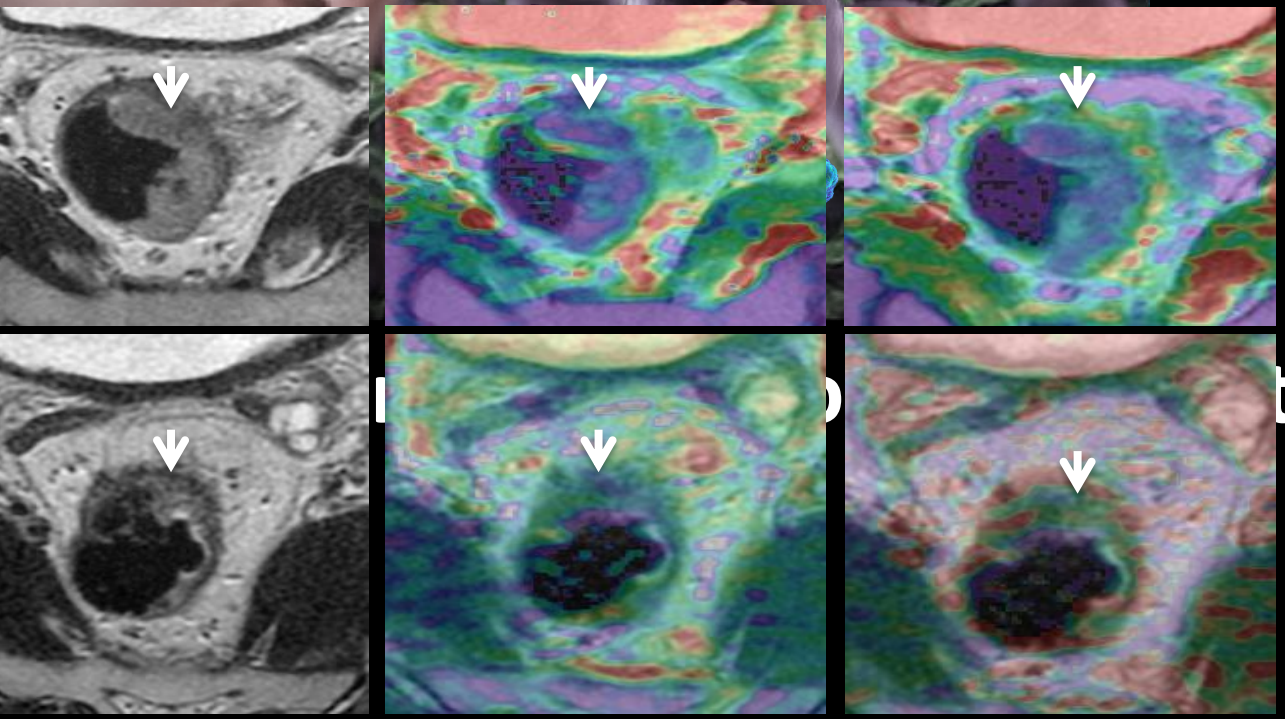

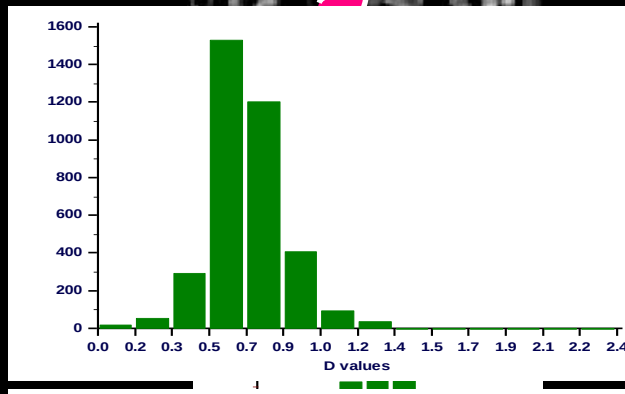

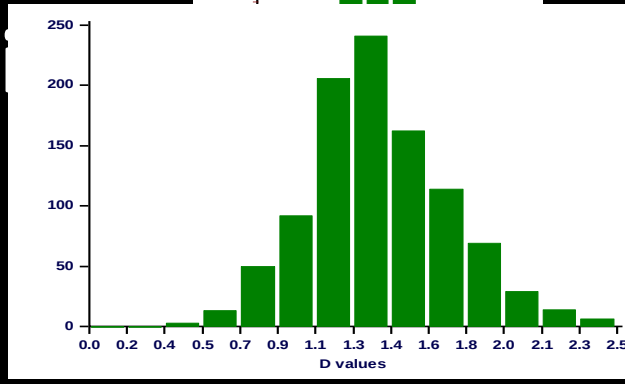

Nougaret, Radiology 2016

DILEMMA

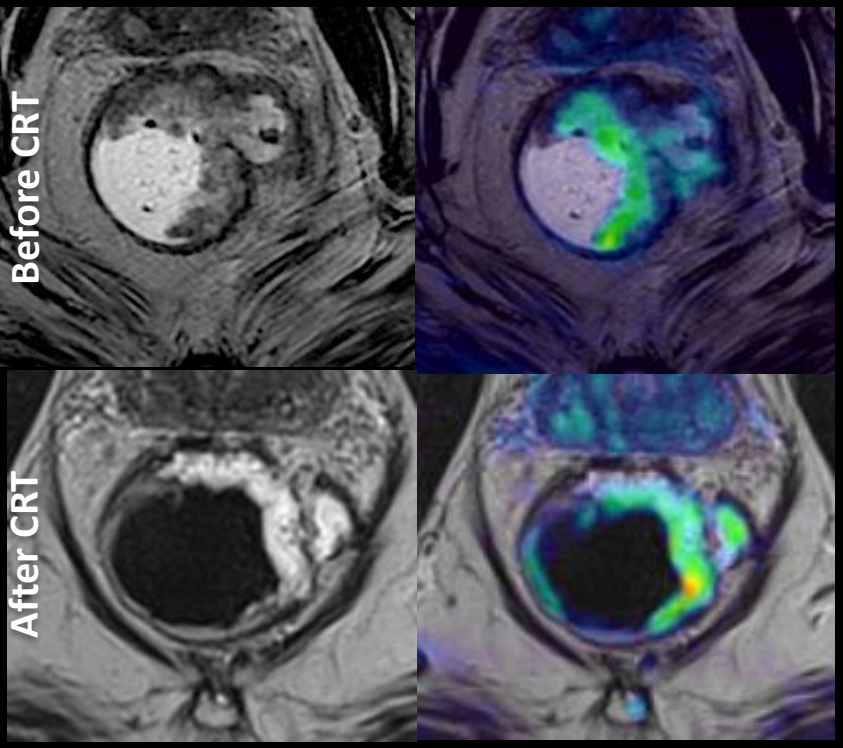

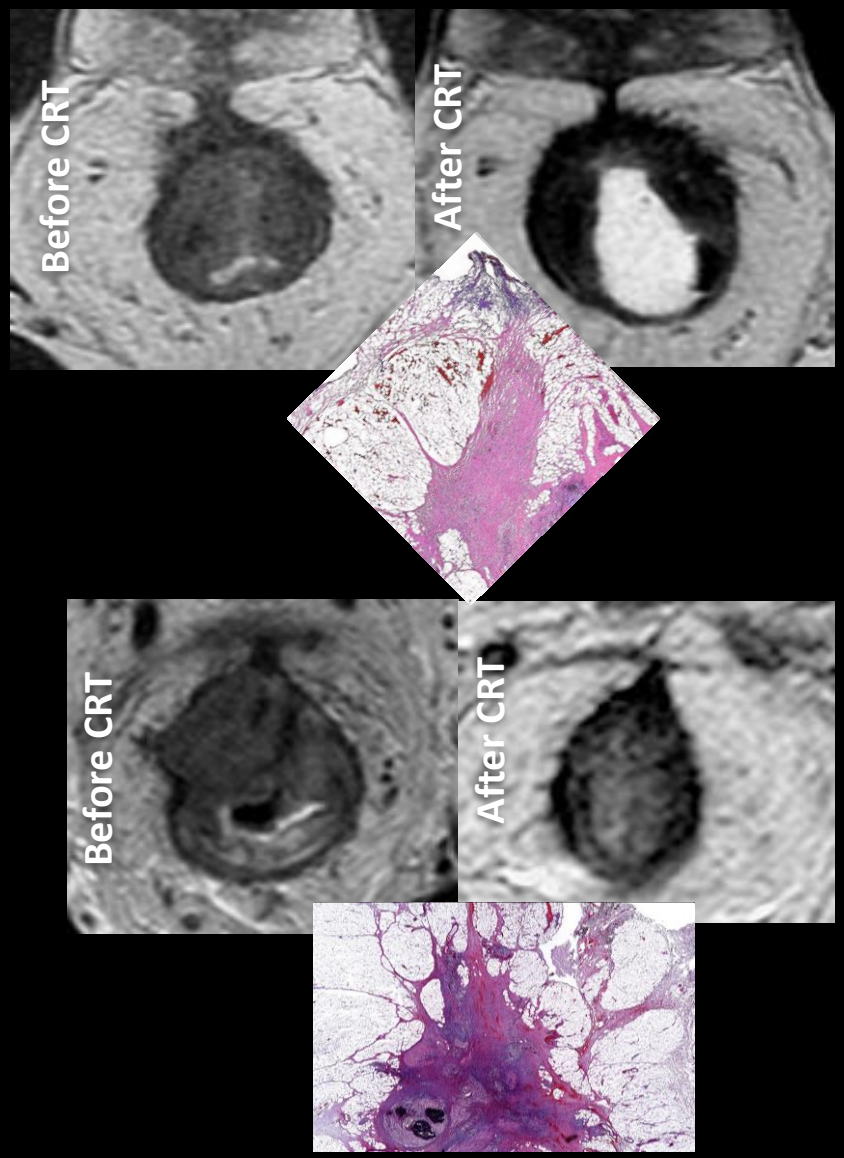

NEW BIOMARKER ?

Circulating microRNAs:

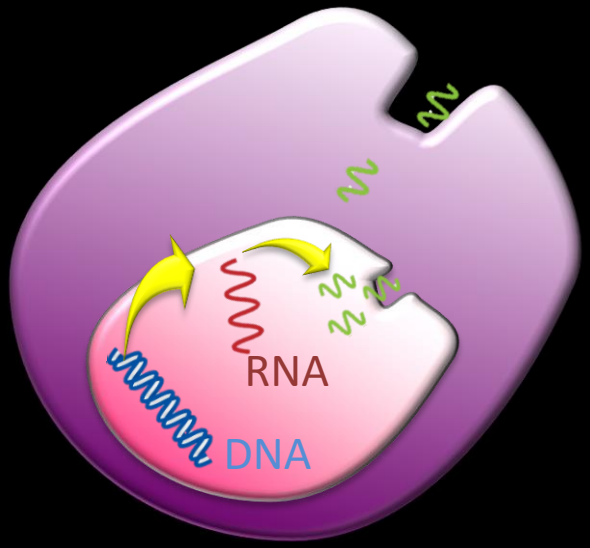

- Circulating miRNA associated with a wide range of diseases such as cancer, autoimmune disease, heart faillure …
- Presence of miRNAs in all body fluids
- Multiple advantages of using circulating miRNAs as biomarkers:
  - ✓ Easy simple blood uptake
  - ✓ High stability of miRNAs in body fluids
- RT-qPCR is the gold standard for the miRNAs detection
  - ✓ High sensitivity and specificity
  - ✓ Easy to use.
  - ✓ Fast (~3 Hours)
  - ✓ Reduced costs

Modified from Cortez, M. A. *et al.* (2011) *Nat. Rev. Clin. Oncol.*

Theradiag
INNOVATION FOR BIOTHERAPIES

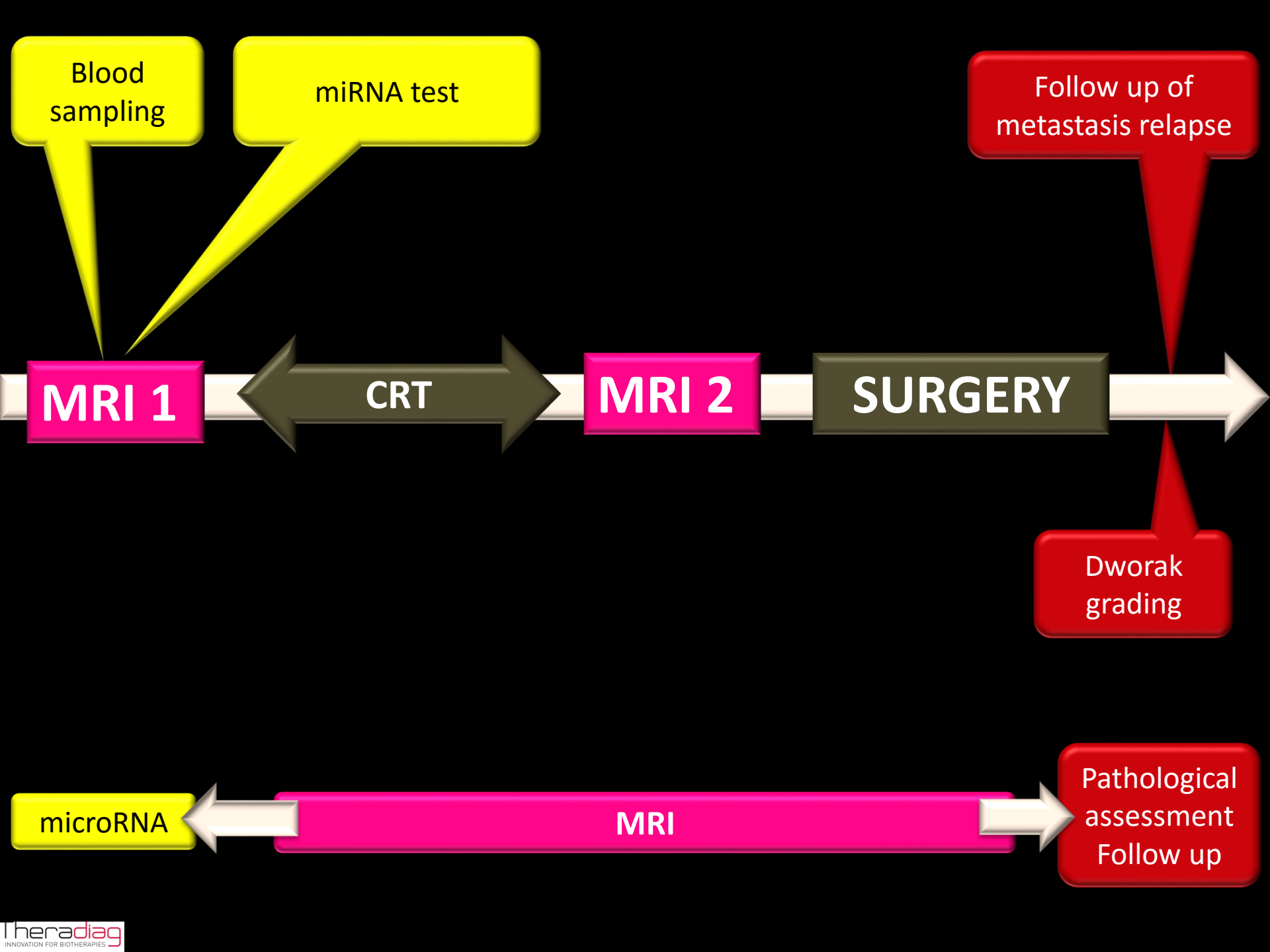

miRNA – DWORAK- MRI

- Patient groups according to Dworak Tumor Regression Grading (TRG)
  - N=34 DWORAK [0, 1, 2]: Non-responders
  - N=35 DWORAK [3, 4]: Responders

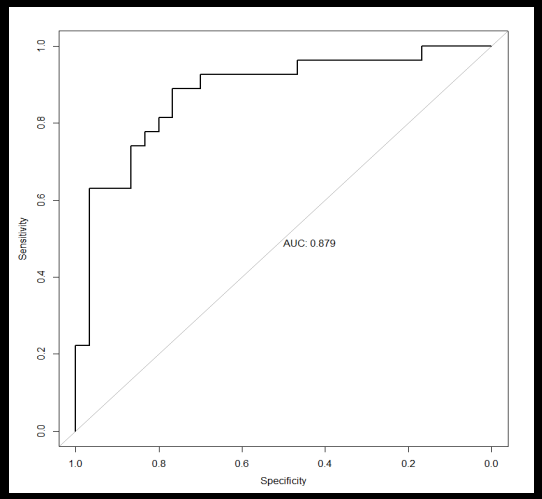

AUC= 0.879

Sensitivity (responder) : 80%
Specificity (non-responder): 78%

The miCRA signature: 8 miRNAs

Characteristics	Total patients n = 69(%)
Tumor Regression Grade	
TRG 0	2 (2.9)
TRG 1	15 (21.7)
TRG 2	18 (26.1)
TRG 3	22 (31.9)
TRG 4	12 (17.4)
Tumor Regression Grade	
Non-responder group TRG 0, 1 and 2	35 (50.7)
Responder group TRG 3 and 4	34 (49.3)

- Combined association ?

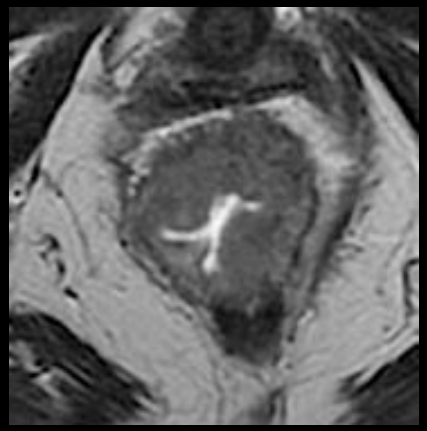

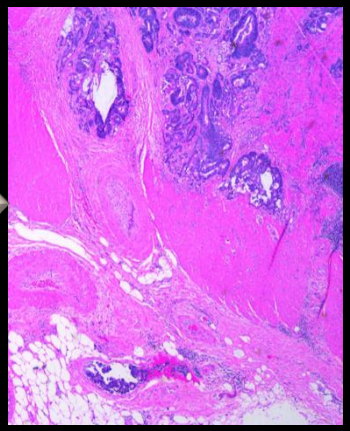

Modeling consistency of a solid tumor by kppv classification

Yann Cabon, Gregory Marin, Nicolas Molinari, Stephanie Nougaret, Isabelle Vachier

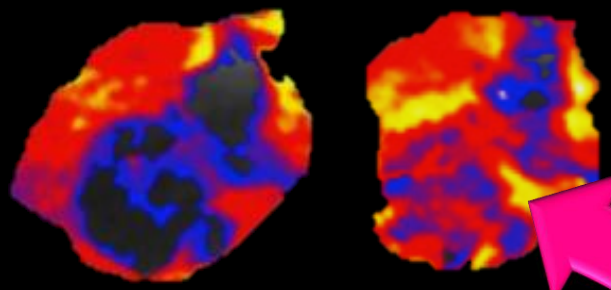

Mathematic and Statistic

Correlation between
Spatial heterogeneity
And genetic heterogeneity

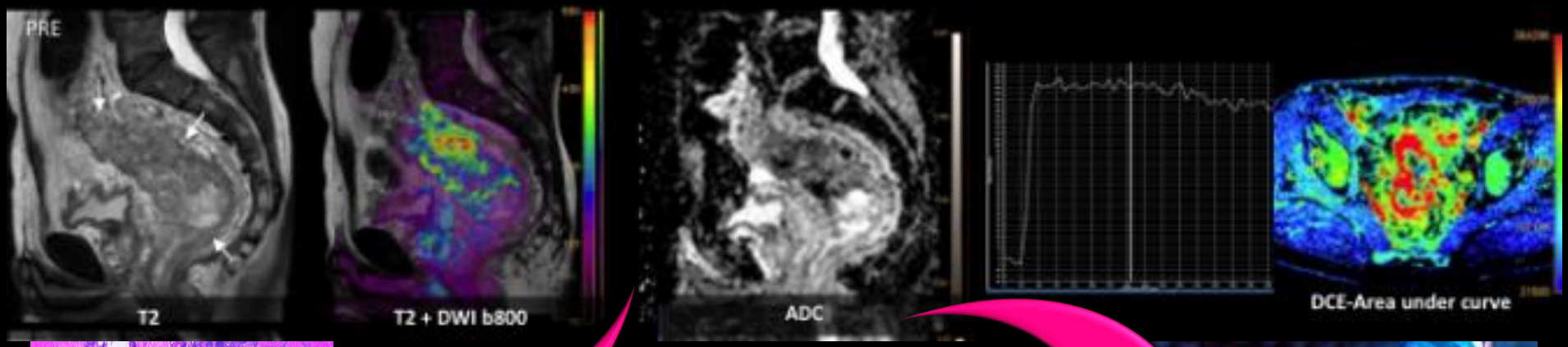

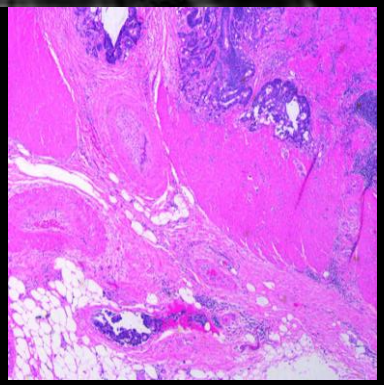

Pathology

Genetic

Faculté de Médecine Montpellier-Nîmes